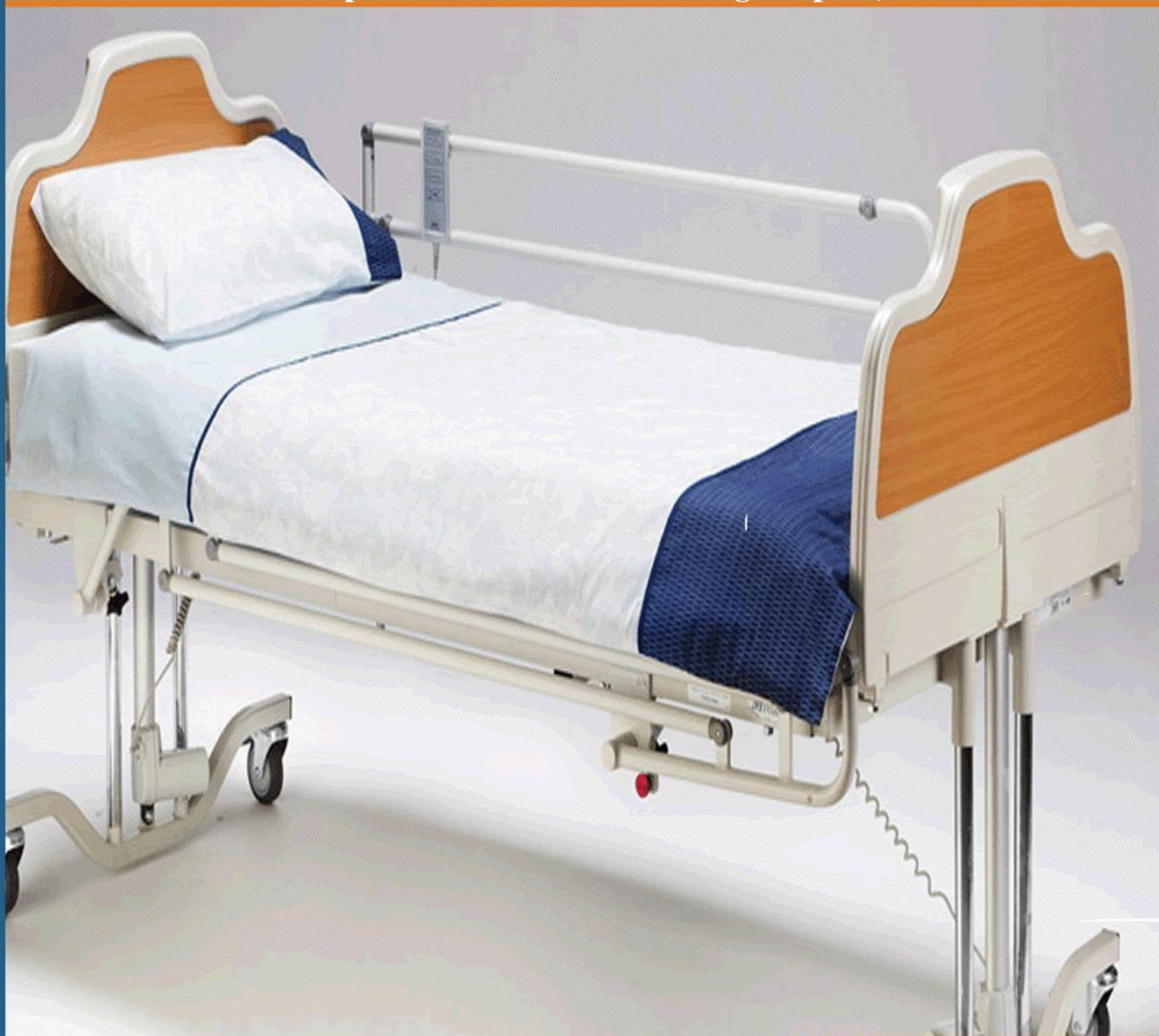

International Journal of Health, Medicine and Nursing Practice


(IJHMNP)

Vesicovaginal Fistula Secondary to Left Ectopic Ureter in a 3-Year-Old Female with Left Ureter-Duplication in Tamale Teaching Hospital, Ghana.



**CARI
Journals**

Vesicovaginal Fistula Secondary to Left Ectopic Ureter in a 3-Year-Old Female with Left Ureter-Duplication in Tamale Teaching Hospital, Ghana: A Case Report

 ^{1*} Benti A. Wewoli, ² Akisibadek A. Afoko

^{1*} Department of Surgery, Urology Unit, Tamale Teaching Hospital, Tamale, Ghana

² Department of Surgery, University for Development Studies, School of Medicine, Tamale, Ghana



<http://orcid.org/0009-0000-4009-2681>

Accepted: 15th Apr 2024 Received in Revised Form: 15th May 2024 Published: 15th Jun 2024

Abstract

Purpose: Vesicovaginal fistula (VVF) is a pathological connection between the bladder and vagina, primarily caused by gynaecological surgery, obstructed labour, and cesarean section. VVF significantly impairs quality of life and is prevalent in developing countries, with Africa seeing up to 130,000 new cases annually. Surgical repair, especially transvaginal approaches, remains the primary treatment. Paediatric cases of VVF, often linked to congenital anomalies like ectopic ureter, are rare and complex to manage.

Methodology: We report a case of a 3-year-old female with continuous urinary leakage since birth, initially flagged for renal anomalies via prenatal imaging. Clinical examination was normal with no distress or developmental issues. Diagnostic assessments, including abdominal ultrasound and micturating cystourethrogram (MCUG), revealed left hydronephrosis, hydroureter, and a definitive vesicovaginal fistula. A CT Urogram confirmed the diagnosis, showing contrast leakage into the vagina.

Findings: Diagnostic cystoscopy revealed a normally positioned right ureteric orifice, while the left was aberrantly positioned near the bladder neck. Culposcopy identified a ureterocele in the posterior fornix of the vagina. During laparotomy, a dilated left distal ureter was observed entering the vagina, indicating true ureter duplication. The surgical intervention involved left ureteric reimplantation using the antireflux method, successfully resolving the anomaly. Post-operative recovery was smooth, with significant improvement in urinary symptoms and no recurrence or complications noted during follow-up.

Unique contribution to theory, policy and practice: VVF secondary to ectopic ureter in paediatric patients is rare but manageable with early diagnosis and tailored surgical intervention. Our case underscores the importance of a multidisciplinary approach and the efficacy of ureteral reimplantation in treating complex congenital anomalies, leading to favourable outcomes and symptom resolution.

Keywords: *Antireflux method, Vesicovaginal fistula, Fistula, Ectopic ureter, Ureter duplication*

1.0 Introduction

Vesicovaginal fistula (VVF) is an abnormal communication between the bladder and the vagina (Rajaian, Pragatheeswarane, & Panda, 2019). VVF is the most common type of genitourinary fistula with major causes being gynaecological surgery, obstructed labour, and cesarean section (Shrestha et al., 2022). The incidence of VVF in Africa alone ranges from 30,000 to 130,000 each year, contributing to at least 3 million women in poor countries living with unrepaired VVF (Wall, 2006).

Surgery remains the main treatment for VVF with transvaginal repair as the most feasible and successful approach with significantly better operative parameters and lower complications (Shamout et al., 2021). Vesicovaginal fistulae (VVF) significantly affect quality of life, with failed surgical repair leading to ongoing morbidity (Neu et al., 2024). Factors contributing to repair failure include iatrogenic injury and endoscopic repair, while combined intra-abdominal/trans-vaginal repair and greater surgeon experience are identified as protective factors against repair failure (Neu et al., 2024).

VVF is a rare condition in paediatric patients, often secondary to congenital anomalies such as ectopic ureter. Congenital cases of VVF are rare, complex and challenging to diagnose, classify and treat, presenting may include menouria, cyclical haematuria and urinary incontinence from birth (Martínez Escoriza et al., 2014). Congenital VVF should be suspected in any girl with urinary incontinence, urinary tract infections from birth, vaginal swelling or hydrocolpometras, as well as in adults with menouria. Physical examination and imaging modalities and helpful in the diagnosis which include cystoscopy during menouria, ultrasound and magnetic resonance imaging (Martínez Escoriza et al., 2014). Congenital VVF can present as an isolated anomaly, or associated with complex malformations of a wide spectrum (Zeineddine et al., 2014). We present a case of VVF in a 3-year-old female with a history of prenatal suspicion of renal abnormalities.

This case report has been reported in line with the SCARE 2023 Criteria (Sohrabi et al., 2023).

CASE PRESENTATION:

2.0 Patient information

A 3-year-old female born at term via spontaneous vaginal delivery, presented with continuous urinary leakage. Prenatal imaging had suggested renal anomalies. System review was normal, with no fever or concerns of developmental milestones.

2.1 Clinical findings

On examination, she appeared comfortable with no signs of distress. The child was clinically well with normal growth and development for her age.

Abdominal examination revealed no tenderness or enlarged organs. No renal angle Tenderness. Auscultation findings were unremarkable. All other systems were clinically unremarkable.

2.2 Diagnostic Assessment

The patient's full blood count (FBC) showed normal levels of haemoglobin and white blood cell count (WBC), and renal function test (RFT) parameters were within normal limits. These findings initially suggested no abnormalities in blood composition and kidney function providing a reassuring baseline for further investigation. However, an abdominal ultrasound revealed left hydronephrosis and hydroureter. This discovery shed light on potential urinary tract obstructions, prompting further scrutiny. Further, a contrast string was observed flowing into the vagina during the micturating cystourethrogram (MCUG) which is a definitive sign of a vesicovaginal fistula. CT Urogramm confirmed the diagnosis with contrast leakage through the vagina.

2.3 Therapeutic Intervention

Following the initial diagnostic tests, further investigations provided crucial details about the patient's condition. During diagnostic cystoscopy, the right ureteric orifice appeared normal, but on the left side, the ureteric orifice was not located in its expected position near. Instead, a small opening was identified near the bladder neck. Subsequent colposcopy revealed the presence of a large ureterocele in the posterior fornix of the vagina, further complicating the diagnosis.

The Parents were counselled for an Exploratory Laparotomy and Ureterreimplantation, the operation was performed under general anaesthesia.

Upon exploration of the abdomen, a dilated left distal ureter was seen, entering the vagina.

The ureter was transected distally, revealing two orifices on the left side: one with a normal calibre and the other markedly dilated, measuring approximately 3 cm in diameter. This observation confirmed the Meyer-Weigert rule of true ureter duplication, indicating a complex anatomical anomaly (Figures 1-4). To address the issue, left ureteric reimplantation using the antireflux method was performed. This surgical intervention aimed to correct the abnormal positioning and function of the ureter, thereby resolving the underlying pathology and mitigating the associated symptoms.

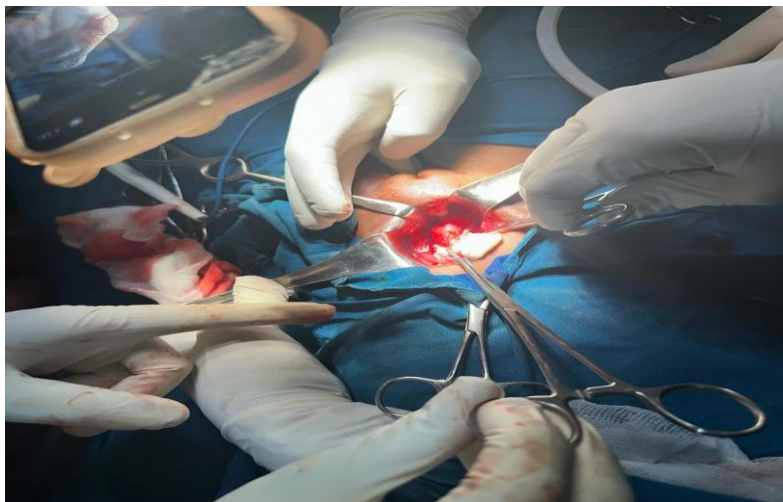


Figure 1: Intra-operative picture at the laparotomy stage

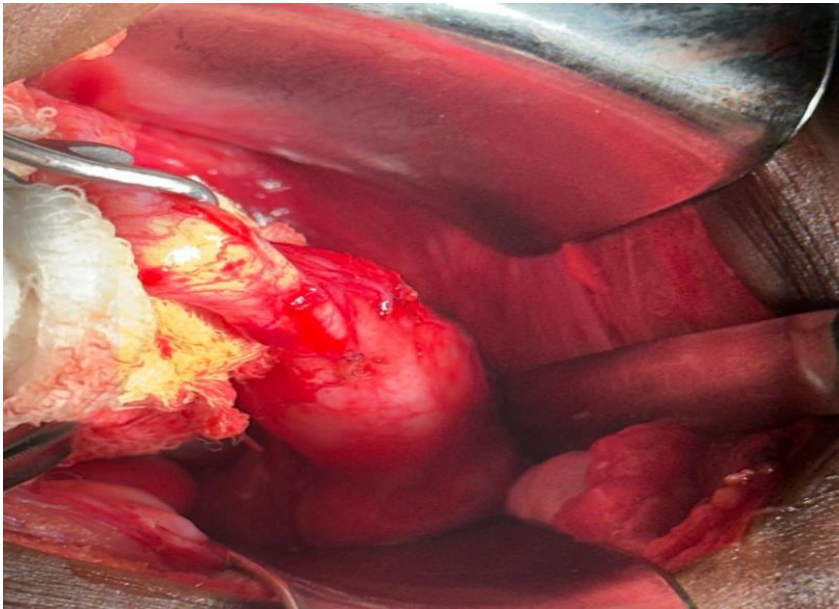


Figure 2: Intra-operative picture showing dilated left distal ureter

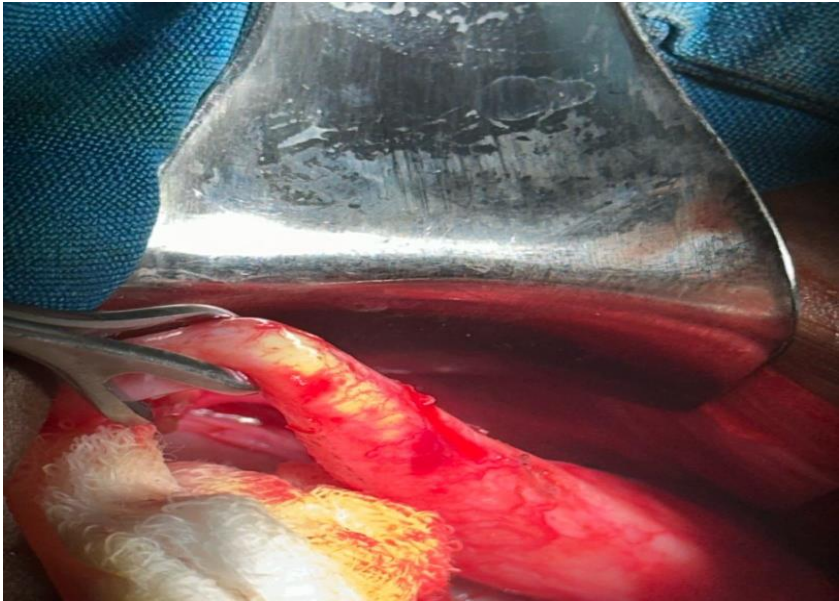


Figure 3: Left dilated distal ureter entering the vagina

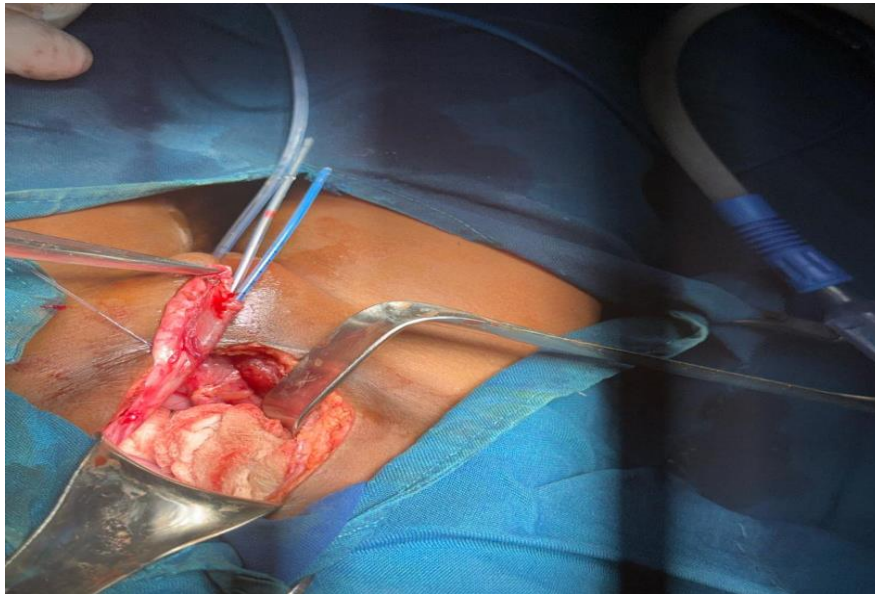


Figure 4: Left ureter-duplication intubated with feeding tubes

2.4 Follow-Up and Outcome

The immediate post-operative condition was smooth and satisfactory with no immediate complications. The patient showed improvement in urinary symptoms with no incontinence of Urine. Follow-up examinations indicated no evidence of recurrence or complications.

3. Discussion

Vesicovaginal fistula (VVF) is a debilitating condition characterized by abnormal communication between the bladder and vagina, resulting in significant negative impacts on a patient's quality of life (El-Azab, Abolella, & Farouk, 2019). Our case presentation underscores the complexity of VVF diagnosis and management, particularly in paediatric patients with congenital anomalies such as ectopic ureter. Ectopic ureter, occurring in only 1 in 2000 newborns with approximately 20% presenting as a single system and rarely manifesting bilaterally, commonly results in urinary incontinence and recurrent UTIs as the main complaints (Kusuma Putra et al., 2023).

While surgical repair remains the cornerstone of VVF management, our case highlights the importance of individualized treatment approaches tailored to the patient's unique clinical presentation. We performed a ureteral re-implantation using the antireflux method. We observed that early diagnosis and surgical intervention are crucial for successful management. Immediate and long-term follow-up resulted in improvement, and no recurring urine incontinence was reported. This corroborates with previous studies that reported that open ureteral re-implantation is still the most common antireflux method with high success rates (Johnson et al., 2021). Antireflux procedure options have expanded to include minimally invasive approaches, which include laparoscopic/robotic reimplantation procedures and endoscopic injections (Johnson et al., 2021).

In paediatric patients, congenital VVF presents unique diagnostic and therapeutic challenges. Our case illustrates the importance of a multidisciplinary approach involving clinical examination and

imaging modalities to confirm the diagnosis and guide treatment decisions. The successful outcome of ureteric reimplantation in our case underscores the efficacy of surgical intervention in addressing complex anatomical anomalies associated with congenital VVF. While the immediate postoperative period was uneventful in our case, long-term follow-up is essential to monitor for recurrence or complications.

Conclusion

Vesicovaginal fistula secondary to ectopic ureter with Ureter Duplication is a rare condition in paediatric patients. Early diagnosis and surgical intervention are crucial for successful management. Ureteral reimplantation is an effective surgical technique in correcting the anomaly and restoring normal urinary function. Timely diagnosis and appropriate surgical intervention can lead to favourable outcomes and the resolution of symptoms.

Patient Consent: Informed consent was obtained from the patient's guardian for the publication of this case report

Ethical Approval: Ethical approval was obtained for the publication of this case report.

Consent: Written informed consent was obtained from the patient's legal guardian for the publication of this case report and accompanying images.

Conflicts of Interest: There is no any conflict of interest.

Funding: No external funding was received for the publication of this case report.

References

- El-Azab, A. S., Abolella, H. A., & Farouk, M. (2019). Update on vesicovaginal fistula: a systematic review. *Arab journal of urology*, 17(1), 61-68.
- Johnson, E. K., Chalmers, D. J., Nelson, C. P., Li, I., Iwaniuk, M., Grant, C., Barnhart, D. C. (2021). Antireflux surgery at national surgical quality improvement program-paediatric hospitals. *The Journal of urology*, 205(4), 1189-1198.
- Kusuma Putra, H. W., Situmorang, G. R., Rodjani, A., & Wahyudi, I. (2023). Bilateral single system ectopic ureters with bilateral urethral insertion and horseshoes kidneys in a female child. *Urology Case Reports*, 49, 102446. doi:<https://doi.org/10.1016/j.eucr.2023.102446>
- Martínez Escoriza, J. C., Palacios Marqués, A. M., López Fernández, J. A., Feliu Rey, E., Martín Medina, P., Herráiz Romero, I., Oliver Sánchez, C. (2014). Congenital vesicovaginal fistula with or without menouria: a literature review. *European Journal of Obstetrics & Gynecology and Reproductive Biology*, 175, 38-48. doi:<https://doi.org/10.1016/j.ejogrb.2014.01.023>

- Neu, S., Locke, J. A., Zhang, B., Saskin, R., & Herschorn, S. (2024). Prevalence and repair patterns of vesicovaginal fistula: a large retrospective population-based cohort analysis. *World Journal of Urology*, 42(1), 149. doi:10.1007/s00345-024-04812-w
- Rajaian, S., Pragatheeswarane, M., & Panda, A. (2019). Vesicovaginal fistula: review and recent trends. *Indian Journal of Urology*, 35(4), 250-258.
- Shamout, S., Anderson, K., Baverstock, R., & Carlson, K. (2021). Evaluation of surgical approaches for vesicovaginal fistulae repair: the case for transvaginal repair as the gold standard. *International Urogynecology Journal*, 32(9), 2429-2435. doi:10.1007/s00192-021-04869-w
- Shrestha, D. B., Budhathoki, P., Karki, P., Jha, P., Mainali, G., Dangal, G., . . . Gyawali, P. (2022). Vesico-Vaginal Fistula in Females in 2010–2020: a Systemic Review and Meta-analysis. *Reproductive Sciences*, 29(12), 3346-3364. doi:10.1007/s43032-021-00832-8
- Sohrabi, C., Mathew, G., Maria, N., Kerwan, A., Franchi, T., & Agha, R. A. (2023). The SCARE 2023 guideline: updating consensus Surgical CAse REport (SCARE) guidelines. *International Journal of Surgery*, 109(5), 1136-1140.
- Wall, L. L. (2006). Obstetric vesicovaginal fistula as an international public-health problem. *The Lancet*, 368(9542), 1201-1209.
- Zeineddine, H. A., Nassif, J., El-Hout, Y., Suidan, F., Saleh, Z. M., & Bazi, T. (2014). Congenital vesicovaginal fistula: spontaneous or forced? Two cases and literature review. *International Urogynecology Journal*, 25(9), 1167-1172. doi:10.1007/s00192-014-2477-8



©2024 by the Authors. This Article is an open access article distributed under the terms and conditions of the Creative Commons Attribution (CC BY) license (<http://creativecommons.org/licenses/by/4.0/>)